INTERNATIONAL JOURNAL OF ADVANCE RESEARCH AND DEVELOPMENT

(Volume 3, Issue 10)

Available online at: www.ijarnd.com

Auto transplantation of a Mandibular Third Molar tooth with immediate root canal therapy: A Case series

Dr. Shwetha R. S.[1], Dr. Venugopal S. S.[2], Dr. K. Rashmi[3], Dr. Sourabh J. Torvi[4], Dr. Jyoti Talawar[5], Suganya Guruswamy[6], Dr. Ranjitha B. B.[7]

[1,2,3,4,5,6]*Assistant Professor, Government Dental College, Bangalore, Karnataka*

[7]*Lecturer, A. J. Institute of Dental Sciences, Mangalore, Karnataka*

ABSTRACT

Autotransplantation of teeth defines as the movement of the tooth from one place to another position within the same individual. It has been practiced for many years with varying degrees of success in the human race. Autotransplantation of teeth ensures maintenance of alveolar bone volume by physiological stimulation of the periodontal ligament. It requires long-term follow up of both clinical and radiographical evaluations. Autotransplantation includes transplantation of embedded, impacted or erupted teeth from one site into other extraction sites or surgically prepared site of the same person. Autotransplantation has been used to replace missing teeth and teeth with poor prognosis. In our study, we have used Schinder's root curvature analysis with immediate root canal therapy which is an additional tool for both endodontist and the oral surgeon. The newer technique of analyzing root curvature in both transplantation tooth and donor site had a great benefit for the success rate of our study. Root curvature analysis helped in both time management and planning of entire transplantation procedure. Radiographs evaluation showed readopted of periodontal tissue and successful masticatory function of the transplanted tooth.

Keywords— *Auto transplantation, Schneider's analysis, Root canal therapy, Periodontal ligament readaptation, Mandibular 3rd molars tooth*

1. INTRODUCTION

Auto transplantation for the younger generation has emerged as a newer technique where in the wisdom tooth and erupted third molars can be utilized for transplantation procedures. The commonest area is the mandibular third molar region which undergoes problem in a dental arch, Most of the time treatment include eradicating the cause or complete removal of the third molar tooth. The earliest case reports of tooth auto transplantation date back to 1950s (1-2). The procedure involves a traumatic removal of a donor's tooth, preparation of a socket at the recipient site, and re implantation of the tooth into the new position. For root completed teeth root canal therapy is followed (3) The transplanted tooth serves as a normal tooth when the procedure is successful (4) both with esthetic and masticatory balance, it also offers arch space maintenance and preserves the volume and morphology of the alveolar bone along with normal structures and balanced occlusion(1,5).

The cost efficiency is very low in comparison to advanced treatment options such as dental implants or prosthetic rehabilitation; it can be performed as a single step surgical procedure which reduces multistage approach and long-term wait period. Auto transplantation can serve as a feasible, fast and economical treatment option for patients especially for the younger generation who has these third molar related problems.

Multiple factors influence the success rate including both the developmental stages of the root and root completion. Other such factors which have a great beneficiary effect are tooth morphology, minimal surgical trauma, the time tooth is preserved outside of the alveolar bone, the shape/site of the recipient socket, and vascularity of the recipient bed. Periodontal ligament (PDL) has a major role in success rate especially for healing in the recipient bed and preservation in donor tooth site. (6, 7) Pulp regeneration, however, occurs in developing teeth (8-9). The viability of PDL cells may be affected during extraction or by extra-oral factors such as variable pH, osmotic pressure, and dehydration (9). Special attention should be paid to preserving the periodontal ligament both in donor site and recipient bed.

2. MATERIALS AND METHOD

Patient with an age group of 24 to 28 years was reported to the department of oral and maxillofacial surgery with a chief complaint of pain and discomfort in the lower back region of the jaw. Clinical examination was done along with radiographic evaluations. The patient had grossly damaged left lower 2nd molar tooth with partially erupted lower 3rd molar. Root curvature

© 2018, www.IJARND.com All Rights Reserved

determination was done by schneider's method of classification (Table 1). Interdental bone was adequate and ramus and soft tissue structure were assessed both clinically and radiographically. Extraction of lower 3rd molar was done with minimal damage to adjacent alveolar bone preserving periodontal tissue. The tooth was handled with outmost care and extra oral root canal treatment was completed with less than 15 minutes. All three canals were located along with accessory canals and filled with regular AH sealer cement and Number 20 of 6% gutta-percha single cone obturation technique. Structures were handled very gently and at most care to preserve the structure around the tooth. Wet gauze was wrapped around the tooth and regular irrigation was done with the use of normal saline while performing root canal procedure. With case 1 closed method of extraction of 2nd molar was done with the use of luxators. Recipient bed was prepared by gentle irrigation using normal saline. The donor's tooth was passively implanted in the recipient bed with minimal apical pressure. The occlusal load was relived so has to minimize trauma over the apical portion of the tooth and periodontal tissue of socket area. Stability was achieved by the figure of 8 wiring, taking the anchorage of a 1st molar with use of 26 gauge stainless steel wire.

In case 2 the patient had discomfort in the left 1st molar tooth with partially erupted 3rd molar tooth. Schneider's radiographic analysis was carried out, which suggested that socket preparation had to be carried accordingly since the donor tooth root had slightly more curvature compared to recipient tooth roots to accommodate in the socket. Atraumatic extraction of 48 was done and extra oral root canal filling was performed identifying all the canals. Obturation was done with no 20 sizes 6% gutta-percha single cone technique. Preservation of soft tissue structure was carried out with least disruption of periodontal attachments. Socket preparation was carried out by using no 701 SS white carbide bur along with minimal bone removal. After tooth was Transplanted to recipient bed stability was achieved with the by use of stainless steel wire. Post-operative care was taken with medication and regular checkup.

2.1 Method of determining curvature

Using schneider's analysis markings are done over radiographic images of the patient. A point is marked on the donor tooth canal orifice representing as Point A. second point is marked at point B where canal flare starts deviating. A straight line is drawn combining both points A and point B. A third point is marked at the apical foramen and termed as point C. Another straight line is drawn joining the point B and point C and then the angles formed between above two intersections are measured. The same is marked over a mesial root with labeling as X, Y, and Z. The recipient tooth undergoes same root curvature evaluation with the same on distal root with point A', point B' and point C' and same land marks over the mesial root with points X', Y' and Z' respectively. The angles are measures on both the root curvature.

Case 1 Analysis (figure 1): The angle formed accordingly to schneider's analysis of distal root that's both donor's tooth and recipient's tooth were less than 5°, and the same measurement of mesial root of both donor and recipient site were around 10°- 20°, hence it was considered as straight curvature for distal root and moderate curvature in mesial root respectively.

Case 2 Analysis (figure 2): The measurements showed according to Schneider's analysis had a slight variation in distal root curvature, both donor roots showed less than 5° and recipient tooth of 10° of distal root. Mesial root of donor tooth showed an angle of 10° to 20°, and recipient tooth mesial root was slightly more than 20°. Hence it was a combination of straight curvature to severe curved. Hence for case 2 the, socket preparation was done accordingly with root curvature evaluation.

Table 1: Classification of root curvature

According to anatomical location	Schinder's classification	Root canal planning	Surgical planning
Apical third	Straight angle < 5	Duration of RCT less than 10 minutes	Apical gradual curve
Middle third curvature	Moderately curve<(10-20)	Duration of RCT Less than 15 minutes	Sickle shape curve
Coronal third curvature	Severely curved If the angle is >20	Duration of RCT More than 20 minutes	Bayonet curve Dilacerated curve

3. SCHNEIDER'S THE ROOT CURVATURE ANALYSIS

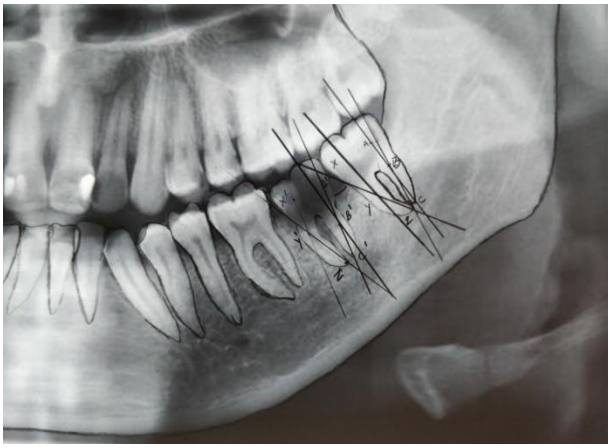

Fig. 1: Radiographic analysis in case 1

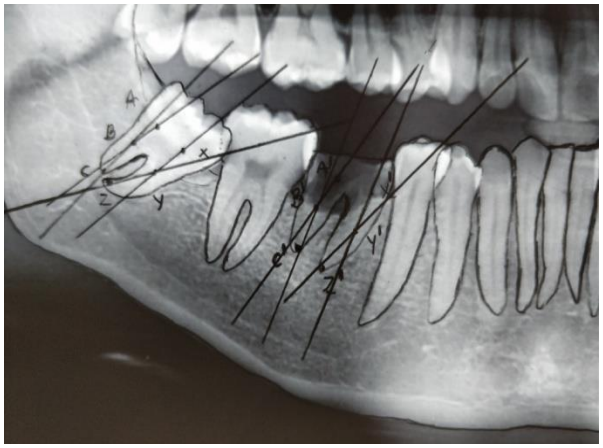

Fig. 2: Radiographic analysis in case 2

Case 1:

Fig. 3: Pre op picture

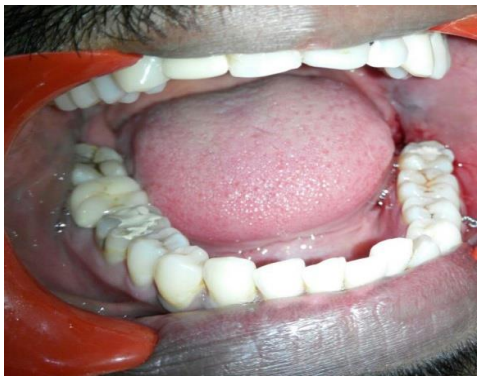

Fig. 4: Post op picture

Fig. 5: Pre-operative OPG

Fig. 6: Immediate postoperative OPG

Fig. 7: Post operative picture

Fig. 8: Occlusion picture pre op

Fig. 9: Post op occlusion with splinting

Case 2:

Fig. 10: Pre op picture

Fig. 11: Post op picture

© 2018, www.IJARND.com All Rights Reserved

Fig. 12: Preoperative picture

Fig. 13: Postoperative picture

Fig. 14: Pre opg

Fig. 15: Post opg

4. DISCUSSION

Transplantation of natural tooth into another region has a high significant advantage over other recent option of tooth rehabilitation. It is considered as one of the choices for rehabilitation of missing dentition. Multiple factors influence the success rate of both transplanted tooth and extracted socket. Tooth includes both the developmental stage and root completion stage with contour and curvature of those roots. Non traumatic surgical extraction with minimally in, the vasive procedure has to be followed to the preserved alveolar bone. The physiological structures', shape, site of the recipient socket along with vascularity of the recipient bed has a major role in success rate.

The donor tooth and recipient site should be both examined meticulously for suitability and accurate fit. (10, 11) The recipient site should have adequate bone support and sufficient soft tissue attachment along with rich keratinized tissue. It allows in maintaining vitality and tooth stability with good prognosis. Both the donor tooth and recipient bed should be free from periapical infection and inflammation. (11) In our both cases the root completion was adequate and both donor and recipient bed were free from periodontal infection or per apical pathology. Soft tissue structure was well preserved in both donor tooth and transplantation bed. Root completion was accurate in our both cases hence root canal treatment was planned prior to transplantation. The curvature of the root canal tooth should be determined preoperatively to avoid procedural errors and subsequent treatment failure. Various classification of root curvatures has been put forward.(12, 13, 14) Schneider's methods of classification according to root curvature angulations it's classified as straight roots, moderately curved and severely curved roots. In our patient's root canal curvature was assessed according to Schneider's method prior to the procedure which was to undergo extra oral root canal therapy with the help of orthopantomogram. (15). Teeth which have sharp root curvatures are not good candidates for transplantation because there is an increased risk of PDL damage during extraction (16,17) in our both cases root curvature were of regular and tapered enough with proper root completion with no history of pathology, ankylosis or incomplete root apex.

Previous studies showed that the viability of periodontal tissue exposed to extra oral environment decreased rapidly after 18 minutes. (18,19) hence in our cases root canal curvatures calculation were planned prior to the procedure and anticipation of procedure and difficulties were handled accordingly by the endodontist. Meticulous planning was done and carful preservation of periodontal tissue around the tooth structures was followed. The duration taken for completion of root canal procedure in both cases was less 15 minutes. Since the root curvatures were pre analyzed it was many benefits to the surgeon to pre plan the surgical procedure to execute accordingly. The analysis was followed according to Schneider's curvature chart. In our first case, both root curvature were showing as mild curvature that was less than 5° of distal root and 10°- 20° of methe sial root, which showed that distal root canal is straight and mesial root is mildly curve. The assessment of these root curvatures helped even our surgeon to plan accordingly the socket bed for transplantation site.

While transplanting the recipient bed requires few preparations according to the sizes of the tooth and space availability. The advantage to this Schneider's curvature analysis helped the surgeon to match and calculate the mesio buccal width and curvatures of both donor tooth and recipient bed prior to the surgical procedure. In our case 1 both mesial and distal roots in were well matched with recipient tooth curvatures respectively, both had shown similar curvature and dimension. In case 2 the distal root curvature matched slightly with recipient bed showing the values as straight curvature to mild curvature. Mesial root showed a slight variation compared to both donor and recipient tooth curvatures, it showed slightly more curved with a value of 20°. The frequency of ledge formation was found to be usually increased if the canal curvature was greater than 20° (20) hence in our case the mesial root with curved canal of more than 20° was handled with outmost care with proper instrumentation care and with

excellent planning by the endodontic. The severity of these root curves was handled meticulously with the reparation of sockets especially in case 2 where it had a severe root curvature. The advantage of these pre radiographic Schneider's analysis gave an excellent prognosis by avoiding extra oral time to the endodontic in root canal preparation. Evaluation of both donor tooth and recipient bed gave an excellent morphological value to the surgeon of both roots and socket contours. Hence this method was of great value in having a better success rate by minimal time intervention due to pre assessment of root curvature. It enhanced the success rate by preserving the periodontal tissue and retaining mastication function along with esthetic integrity. Long term evaluation is recommended for long lasting prognosis (21), Post-operative radio graph in one of the case showed a well-defined periodontal ligament reattachment after a period of time in transplanted tooth site. In our both cases the recipient sites had sufficient bony support and keratinized mucosa to enhance post-operative stability. When it comes to choice of Replacement of missing tooth and irradiating problem related to 3rd molar tooth one has to considered as auto transplantation as an alternate to tooth replacement. (22) Transplanted tooth should be held passively to allow slight minor movement which indeed reduces the potential of ankylosis and adverse effects on the periodontal and pulpal healing of the tooth. (23, 24) hence in our case, passive splinting was done along with minimal occlusal force over the transplanted tooth.

5. CONCLUSION

Auto transplantation of mandibular third molar does provide various options for replacement of missing and damaged tooth. The science of auto transplantation has progressed as evidence by the high success rate over since a few decades. The transplanted tooth serves in both maintaining natural space preserving bone volume and maintaining the naturally available periodontal structures in and around. The key to success will always be the planning and execution of the procedure accordingly.

Extra oral Root canal treatment is one of the challenging tasks for the endodontist due to the complex anatomy of the 3rd molar. Handling the severity of root curvatures and time dependent management is an import aspect in extra oral root canal therapy. The hindrances to the endodontist are usually caused by root curvature and presence of accessory canal. The curvature may vary from gradual curvature to sharp curvature of the canal extending up to the apex and gradual curvature of the canal with a straight apical ending. Negotiating these canals depends on the size and construction of the canal, the degree of curvature, size, and flexibility of the instrument, along with the skills of the operator. Preoperative assessment of the horizontal and vertical variations of the canals should be done and a proper instrumental technique is necessary to avoid procedural errors. The new method of curvature analysis of these roots and performing accordingly gave a high success rate and good prognosis.

Transplantation of the tooth and preparation of the recipient bed had an important role in the success rate. Hence the surgeon had a choice to evaluate by Schneider's root curvature analysis prior to the procedure and prepare the transplantation bed accordingly. It was the skillful job to the surgeon to execute the procedure according to the planned analysis good success rate. Hence forth one should consider these root curvature analysis tools which have a major role in the auto transplantation cases.

6. REFERENCES

[1] Apfel H. Preliminary work in transplanting the third molar to the first molar position. J Am Dent Assoc. 1954;48(2):143-50
[2] Miller HM. Transplantation and reimplantation of teeth. Oral Surg Oral Med Oral Pathol. 1956;9(1):84-95.
[3] Patel S, Fanshawe T, Bister D, Cobourne M. Survival and success of maxillary canine autotransplantation: a retrospec-tive investigation. Eur J Orthod. 2010.
[4] Sugai T, Yoshizawa M, Kobayashi T, Ono K, Takagi R, Kitamura N, et al. Clinical study on prognostic factors for autotransplantation of teeth with complete root formation. Int J Oral Maxillofac Surg. 2010; 39(12).
[5] Arikan F, Nizam N, Sonmez S. 5-year longitudinal study of survival rate and periodontal parameter changes at the site of maxillary canine autotransplantation. J Period, 79: 595–602, 2008.
[6] Tsukiboshi M. Autotransplantation of teeth. Quintessence, Tokyo; 10–181, 2001.
[7] Lai FS. Autotransplantation of an unerupted wisdom tooth germ without its follicle immediately after removal of an impacted mandibular second molar: a case report. J Can Dent Assoc, 75: 205–208, 2009.
[8] Northway W. Autogenic dental transplants. Am J Orthod Dentofacial Orthop, 121: 592–593, 2002.
[9] Czochrowska EM, Stenvik A, Album B, Zachrisson BU. Autotransplantation of Orthod Dentofacial Orthop, 118: 592–600, 2000.
[10] Teixeira CS, Pasternak Jr B, Vansan LP, Sousa-Neto MD. Autogenous transplantation of teeth with complete root for-mation: Two case reports. Int Endod J. 2006; 39(12):977-85.
[11] Clokie CM, Yau DM, Chano L. Autogenous tooth trans-plantation: an alternative to dental implant placement? J Can Dent Assoc. 2001;67(2):92-6.
[12] Peter OA. Current challenges and concepts in the preparation of root canal system: A review. J Endod 2004; 30:559‑67.
[13] Estrela C, Bueno MR, Sousa‑Nets MD, Pécora JD. Method for determination of root curvature radius using cone‑beam computed tomography images. Braz Dent J 2008; 19:114‑8.
[14] De Moor RJ, Deroose CA, Calberson FL. The radix entomolaris in mandibular first molars: An endodontic challenge. Int Endod J 2004; 37:789‑99.
[15] A brief review of the methods used to determine the curvature of root canals. J Res Dent 2015; 3:57-63.
[16] Teixeira CS, Pasternak Jr B, Vansan LP, Sousa-Neto MD. Autogenous transplantation of teeth with complete root for-mation: Two case reports. Int Endod J. 2006;39(12):977-85.
[17] Cohen AS, Shen TC, Pogrel MA. Transplanting teeth successfully: autografts and allografts that work. J Am Dent Assoc. 1995; 126(4):481-5; quiz 500.
[18] Anderson JO.peridontal healing after replantation and autotransplantation of incisors in monkeys.int J oral surg 1981;10:54-61.

[19] Anderson JO.effect of extra-alveolar and storage media upon periodontal and pulp healing replantation of mature incisors in monkeys.int J oral surg 1981;103-43-53.
[20] Jafarzadeh H, Abbott PV. Ledge formation: Review of a great challenge in endodontics. J Endod 2007; 33:1155‑62.
[21] Kim E, Jung JY, Cha IH, Kum KY, Lee SJ. Evaluation of the prognosis and causes of failure in 182 cases of autogenous tooth transplantation. Oral Surg Oral Med Oral Pathol Oral Radiol Endod. 2005; 100(1):112-9.
[22] Clokie CM, Yau DM, Chano L. Autogenous tooth trans-plantation: an alternative to dental implant placement? J Can Dent Assoc. 2001; 67(2):92-6.
[23] Oskar Bauss, Rainer Schwestka-Polly, Reinhard Schilke, Stavros Kiliaridis. Effect of different splinting methods and fixation periods on root development of autotransplanted immature third molars. J Oral Maxillofac Surg, 63: 304–310, 2005.
[24] Pogrel MA. Evaluation of over 400 autogenous tooth transplants. J Oral Maxillofac Surg, 45: 212–216, 1987.
[25] Cohen AS, Shen T.C, Pogrel MA. Transplanting teeth successfully: autografts and allografts that work. J Am Dent Assoc, 126: 481–485, 1995.
[26] Thomas S, Turner SR, Sandy JR. Autotransplantation of teeth: is there a role? Br J Orthod, 25: 275–282, 1998.
[27] Tsukiboshi M, Andreasen J, Asai Y. Autotransplantation of teeth. Chicago; Quintessence, 2001:10–4, 97, 152–67.
[28] Mejare B, Wannfors K, Jansson L. A prospective study on transplantation of third molars with complete root formation. Oral Surg Oral Med Oral Pathol Oral Radiol Endod 2004;97:231–8.
[29] Lindskog S, Blomlof L. Influence of osmolality and composition of some storage media on human periodontal ligament cells. Acta Odontol Scand 1982;40: 435–41.
[30] Gilijamse M, Baart JA, Wolff J, Sandor GK, Forouzanfar T. Tooth auto transplantation in the anterior maxilla and mandible: retro-spective results in young patients. Oral Surg Oral Med Oral Pathol. 2016;122:187–92.

© 2018, www.IJARND.com All Rights Reserved